

CLINICAL GUIDELINE FOR THE ORTHOPEDIC HIP SURVEILLANCE OF PATIENTS WITH
CEREBRAL PALSY OR OTHER MOTOR DISEASE

Submitted to Clinical Excellence

Date December 13, 2024

Prepared by:

Alice Phillips, MD, MPH – Director for Ambulatory Quality

Kristen Taylor, DO – Physical Medicine and Rehabilitation

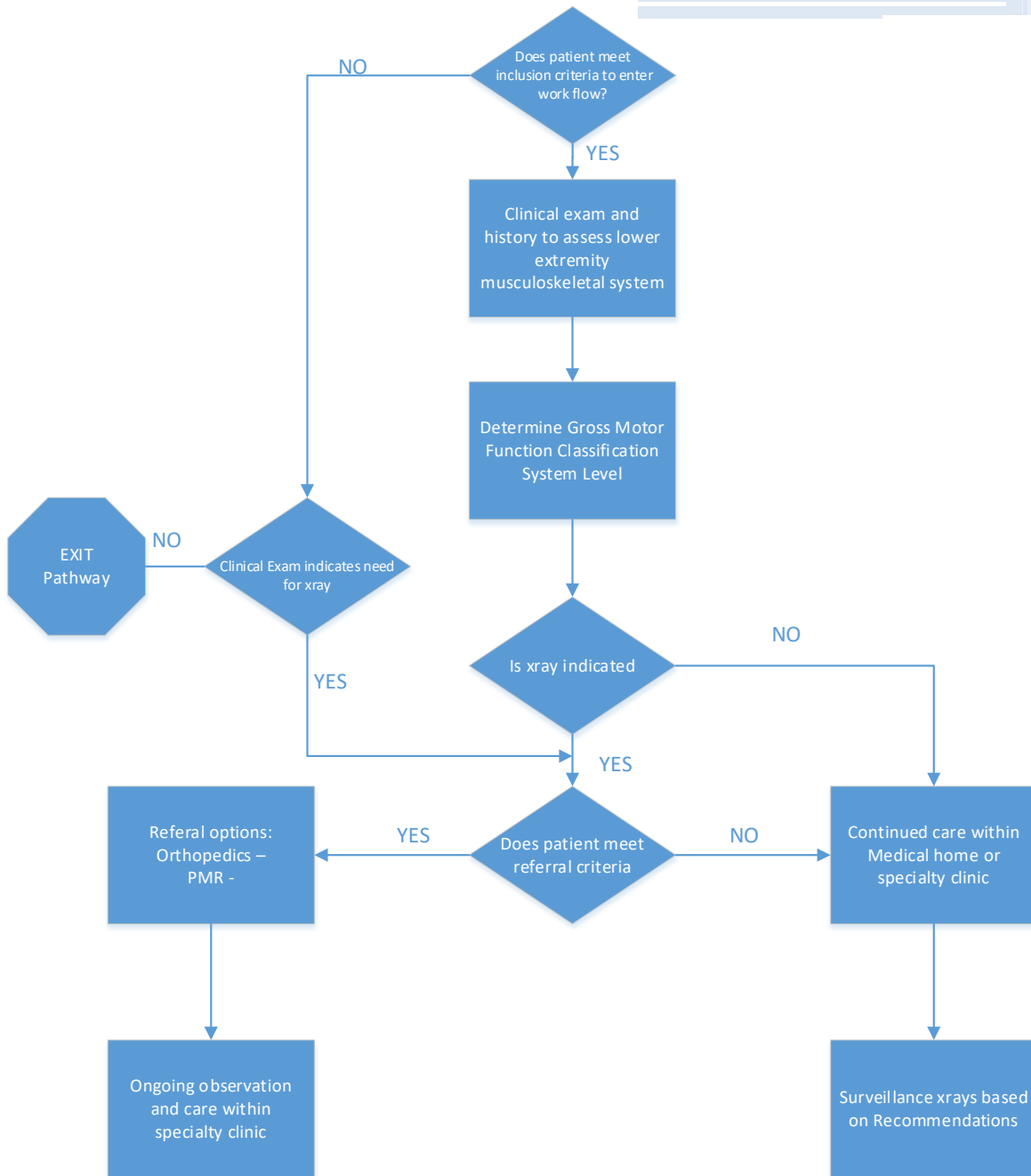
Taylor Dodgen, MD – Orthopedics

Yvette Johnson, MD, MPH – Medical Director of Nest Clinic

Pamela Sherman, MD – Orthopedics

Sam James, BSN, RN, LP – Neuromuscular Coordinator

CLINICAL GUIDELINE FOR THE ORTHOPEDIC HIP SURVEILLANCE OF PATIENTS WITH CEREBRAL PALSY OR OTHER MOTOR DISEASE



CLINICAL GUIDELINE FOR THE ORTHOPEDIC HIP SURVEILLANCE OF PATIENTS WITH CEREBRAL PALSY OR OTHER MOTOR DISEASE

I. Inclusion Criteria

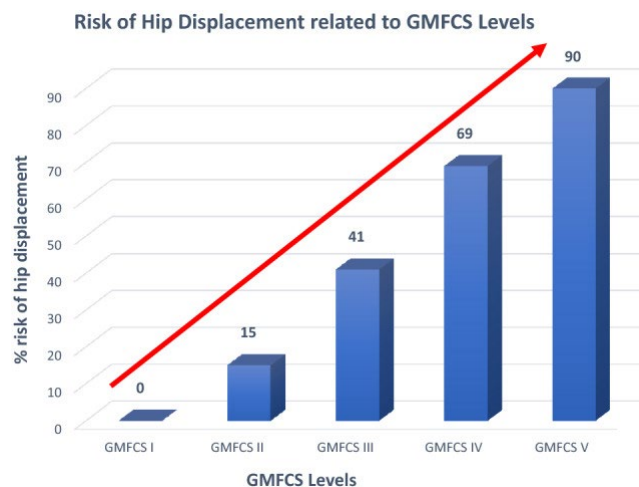
- a. Age 12 months and up
- b. Diagnosis including but not limited to
 - i. Cerebral Palsy
 - ii. Hypertonia
 - iii. Hypotonia
 - iv. Gross motor milestone delays
 - v. Global Developmental Delay
 - vi. Other Neuromuscular or Seizure Disorder diagnosis that may create motor delays. EX: Lennox Gastaut
 - vii. Wheelchair dependent patients
- c. Patients with abnormal hip physical exam

II. Exclusion Criteria

- a. Patients less than 12 months of age
- b. Patients with birth history risk factors for developmental dysplasia of hip for example breech presentation at birth
- c. Patients with no tone, genetic or central nervous system abnormalities

III. Background/Definitions

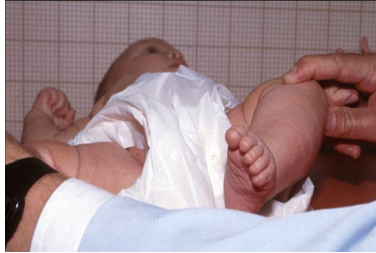- a. Cerebral Palsy is the most common case of physical disability affecting children with a prevalence of 2 per 1000 live births
- b. Hip dysplasia is the second most common problem after equinus
- c. Incidence of hip displacement is approximately 35%
- d. Patients with Cerebral Palsy or an identified disorder impacting their motor development are at increased risk for development of hip dysplasia
- e. Hip surveillance refers to an ongoing physical exam AND radiographic imaging of patients determined to be at risk
- f. Physical exam alone is a poor indicator of hips at risk. Early detection and referral results in long term improved clinical outcomes and decreased patient pain
- g. Surveillance frequency varies depending upon severity of symptoms
- h. The Gross Motor Function Classification System helps define and stratify this risk and provide surveillance recommendations



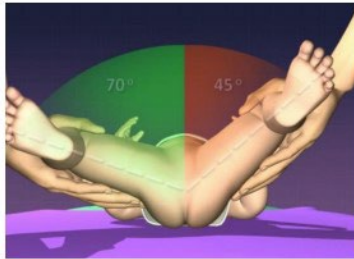
CLINICAL GUIDELINE FOR THE ORTHOPEDIC HIP SURVEILLANCE OF PATIENTS WITH CEREBRAL PALSY OR OTHER MOTOR DISEASE

IV. Clinical Exam

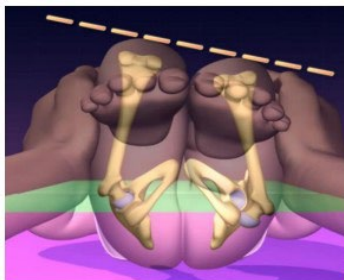
- a. Clinical examination of the hips can supplement this decision pathway as a means of diagnosing hip instability, decreased hip abduction or leg length discrepancy
- b. Asymmetry of hip abduction is frequently reported by parents as tightness noted during diaper change



- c. Examination could include:
 - i. For Ambulatory patients gait should be observed
 - ii. Assessment for limited hip abduction
 1. Place patient in supine position
 2. Stabilize pelvis with hips and knees flexed to 90 degrees
 3. Thighs abducted gently and simultaneously



- iii. Assessment for limb length discrepancy – Galeazzi Test
 1. Place patient supine
 2. Flex hips to 90 degrees while in neutral adduction/abduction
 3. Face examination surface with eyes level of infant's knees
 4. Assess knee height for symmetry

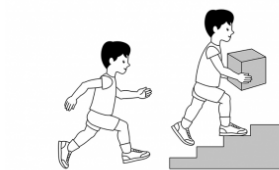


CLINICAL GUIDELINE FOR THE ORTHOPEDIC HIP SURVEILLANCE OF PATIENTS WITH CEREBRAL PALSY OR OTHER MOTOR DISEASE

d. KEY: A normal physical exam will not change workflow if history suggestive of risk BUT an abnormal physical exam can create need to enter the workflow

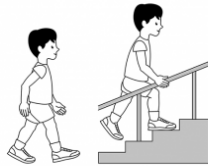
- V. Gross Motor Function Classification System (GMFCS)
- Five level classification system
 - Focuses on self-initiated movements
 - Movements include sitting, transfers and mobility

GMFCS Levels



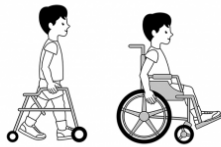
GMFCS Level I

- Can walk indoors and outdoors and climb stairs without using their hands for support.
- Can run and jump.
- Has decreased speed, balance, and coordination.



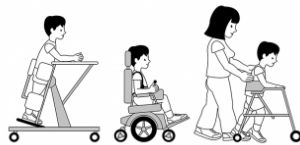
GMFCS Level II

- Can walk indoors and outdoors and climb stairs using a railing.
- Experiences difficulty with uneven surfaces, inclines, or while in crowds.
- Can minimally run or jump.



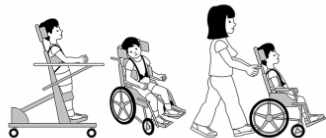
GMFCS Level III

- Walks with assistive mobility devices indoors and outdoors on level surfaces.
- May be able to climb stairs using a railing.
- May propel a manual wheelchair; may require assistance for long distances or uneven surfaces.



GMFCS Level IV

- Walking ability is severely limited, even with assistive devices.
- Uses a wheelchair most of the time and may propel their own power wheelchair.
- May participate in standing transfers.


























































































GMFCS Level V

- Has physical impairments that restrict voluntary movement control and the ability to maintain head and neck position against gravity.
- Experiences impairment in all areas of motor function.
- Can't sit or stand independently, even with adaptive equipment.
- Can't independently walk, though may be able to use powered mobility devices.

CLINICAL GUIDELINE FOR THE ORTHOPEDIC HIP SURVEILLANCE OF PATIENTS WITH CEREBRAL PALSY OR OTHER MOTOR DISEASE

VI. Radiographic/Surveillance Recommendations

Age (Years)	GMFCS I	GMFCS II	GMFCS III	GMFCS IV & V		Any GMFCS Level with Winters Gage Hicks Gait Type IV	
							
2.0 years or at ID		 	 	 	 	 	 
2.5							
3			 				
3.5							
4			 				
5			 				
6		 	 			 	
7			 				
8		 	 				
9							
10		 	 				
11							
12 to 16 or Skeletal Maturity (SM)			Bi-Annually to SM†  	Bi-Annually to SM†  	Annually to SM†  	Annually to SM†  	Bi-Annually to SM†  
Skeletal Maturity (SM) is defined as closure of the triradiate cartilage.							
Notes re: Initiation	If CP is diagnosed or suspected after age 2 but before 4 years, begin surveillance immediately. Do not wait until 4 years of age.		If CP is diagnosed or suspected after age 2, immediately begin 12-monthly schedule for a minimum of 24 months.		If CP is diagnosed or suspected after age 2, immediately begin 6-monthly schedule and continue for a minimum of 24 months at that frequency.		If CP diagnosed or suspected after age 2 but before age 4, begin surveillance immediately.
†If there is any doubt of the GMFCS level, follow the recommendation for the higher level.							
Frequency Modifiers			* Do not reduce from previous higher frequency if: (1) 24 months of surveillance have not yet been completed based on a child's surveillance start date; (2) stability is not yet achieved over a period of 2 years. Stability is defined as < 10% change in MP over a 12 month period; OR (3) MP > 30%.				
Discharge	Discharge if MP ≤30% at age 10 (unless WGH Gait Type IV).		Discharge if skeletally mature and MP ≤30%. † In the presence of pelvic obliquity associated with clinical or radiographic evidence of increasing scoliosis, the hip/s continue to be at risk and should ideally be monitored even beyond skeletal maturity.				

Legend:  : Clinical Examination  : AP Pelvis Radiograph
 GMFCS: Gross Motor Function Classification System (Palisano R et al., 1997. Illustrations reproduced with permission and copyright © Bill Reid, The Royal Children's Hospital, Melbourne, AUS.)
 WGH Gait Type IV: Winters, Gage, Hicks Gait Type IV Hemiplegia (Winters T, Gage J, Hicks R, 1987; Rodda J & Graham HK, 2001. Illustrations reproduced with permission and copyright © Bill Reid, The Royal Children's Hospital, Melbourne, AUS.)

NOTE: For kids 12 -24 months with tone abnormalities consider hip x-rays within this age range

VII. Imaging recommendations: AP Frogleg with clear messaging to Radiology of diagnostic reason for imaging

VIII. Referral Criteria

- a. Clinical History positive for pain with movement of hips
- b. Clinical Exam shows less than 30 degrees of hip abduction
- c. Abnormal radiographic findings including but not limited to
 - i. suspicious for migration over 30 percent

CLINICAL GUIDELINE FOR THE ORTHOPEDIC HIP SURVEILLANCE OF PATIENTS WITH CEREBRAL PALSY OR OTHER MOTOR DISEASE

- ii. hip subluxation or dislocation
 - iii. Other radiographic findings of concern to clinician
- d. Referral patterns could include:
 - i. Physical medicine and rehab if equipment or orthotic needs due to motor delays
 - ii. Orthopedics if abnormal hip x-ray or provider concerns for need for long term neuromuscular follow up

CLINICAL GUIDELINE FOR THE ORTHOPEDIC HIP SURVEILLANCE OF PATIENTS WITH CEREBRAL PALSY OR OTHER MOTOR DISEASE

References:

Aroojis A, Mantri N, Johari AN. Hip Displacement in Cerebral Palsy: The Role of Surveillance. *Indian J Orthop.* 2020 Jun 11;55(1):5-19. doi: 10.1007/s43465-020-00162-y. PMID: 33569095; PMCID: PMC7851306.

Soo B, Howard JJ, Boyd RN, Reid SM, Lanigan A, Wolfe R, Reddihough D, Graham HK. Hip displacement in cerebral palsy. *J Bone Joint Surg Am.* 2006 Jan;88(1):121-9. doi: 10.2106/JBJS.E.00071. PMID: 16391257.

Hägglund G, Lauge-Pedersen H, Wagner P. Characteristics of children with hip displacement in cerebral palsy. *BMC Musculoskelet Disord.* 2007 Oct 26;8:101. doi: 10.1186/1471-2474-8-101. PMID: 17963501; PMCID: PMC2194677.

American Academy for Cerebral Palsy and Developmental Medicine (2024) Hip Surveillance in Cerebral Palsy. Retrieved from: [Hip Surveillance in Cerebral Palsy | AACPDM - American Academy for Cerebral Palsy and Developmental Medicine](#)

Government of Western Australia Child and Adolescent Health Service (2024) Hip Assessment. Retrieved from: [Hip assessment \(health.wa.gov.au\)](#)