

# Chest wall deformities: pectus excavatum and carinatum



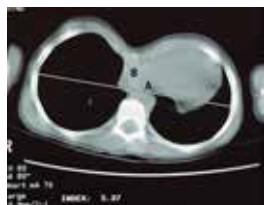By José L. Iglesias, M.D., Medical Director, Pediatric Surgery

The two most common congenital chest wall deformities fall into the categories of pectus carinatum (sternal protrusion) and pectus excavatum (sunken sternum). Chest wall deformities are more common in Caucasian boys. A specific etiology of the conditions still remains elusive, but the predominant theories focus on disturbances in the growth of the sternum and costal cartilages and biomechanical factors. Supporting these hypotheses are the associated conditions, which include Marfan's syndrome, connective tissue disorders (e.g., Ehlers-Danlos), scoliosis and congenital diaphragmatic hernias.

## Pectus excavatum (also known as funnel chest)

### Presentation

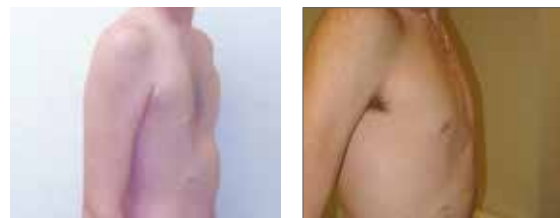
- Incidence of about 1:400, with 3:1 male to female ratio
- Usually noticed in the first year of life and tends to markedly increase in severity during puberty; spontaneous regression only occurs rarely
- Highly variable degree of deformity with possible angulation of sternum or may be mixed with a pectus carinatum deformity
- Possible cardiovascular or pulmonary impairment, which is most noticeable with exertion
- Significant psychological distress and poor body image in many patients. Some of these patients may require psychological evaluation



### Workup

- History and exam (remember to also look for Marfanoid features)
- Chest X-ray
- Pectus (Haller) index CT scan:
  - Ratio of the widest inner chest width (A) /inner sternum to spine length at the deepest point of the deformity (B) with a normal breath
  - Significant defect  $\geq 3.25$  (normal 1.9-2.7)
- Cardiac ECHO
- Cardiac MRI: evaluation of right ventricle dysfunction
- Pulmonary function test (PFT)
- Screening for possible nickel allergy

For younger asymptomatic or minimally symptomatic patients, including those who are not yet ready to consider repair, the last three to four studies may be delayed for a subsequent follow-up.



Before

After

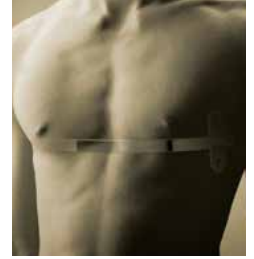### Indication for surgical referral

- Symptomatic defect
- Progression of the defect
- Paradoxical movement of the chest with inspiration
- Pectus index  $>3.0$
- Significant cardiac compression or displacement, especially if mitral valve prolapse, murmurs or conduction abnormalities are discovered
- Abnormal pulmonary function studies, especially if restrictive disease is noted
- Significant psychological distress or body image problems
- Failed prior repairs

### Repair

**Timing:** dependent on the degree of symptoms and anatomy, but generally early adolescence is the most ideal (prior to the stiffness of skeletal maturity, but closer to full growth to minimize recurrence). Try to avoid in the  $<10$  years of age if possible. Repair can be done into adulthood.

# Chest wall deformities: pectus excavatum and carinatum



By José L. Iglesias, M.D.

## Surgical options

**Nuss minimally invasive repair of pectus excavatum (MIRPE):** Uses small, lateral chest incisions and a thoracoscope to place a stainless steel brace underneath the sternum. Cryoablation is used to aid in post-operative pain management. No excision of cartilage is needed. The brace is removed in two to three years as an outpatient procedure. Most patients are candidates for this procedure, but some very asymmetric deformities may require other approaches.

**Ravitch repair\*:** A longer anterior thoracic incision is used to excise the abnormally shaped cartilages in a subperichondrial plane. An osteotomy is often made in the sternum to position it appropriately. A stainless steel brace is placed to keep the sternum in position while the cartilage grows to the sternum (approximately two years). Non-operative options for mild deformities, posture control, exercise program (e.g., deep breathing, pushups) and annual follow-up may be appropriate. Compliance is important for optimal results.

## Pectus carinatum (also known as pigeon chest)

### Presentation

- One-fifth as common as pectus excavatum with 4:1 male predominance
- Presents later than excavatum deformity (50 percent by 11 years of age) also worsens during puberty
- May be asymmetric or mixed with an excavatum component to the deformity
- Associated with congenital heart disease, but otherwise it is less likely to have cardiopulmonary symptoms
- May have sternal or peristernal pain

### Workup

- History and exam (remember to also look for Marfanoid features)
- In select cases, chest X-ray, CT scan, ECHO or PFTs may be needed

For younger asymptomatic or minimally symptomatic patients, including those who are not yet ready to consider repair, the last three to four studies may be delayed for a subsequent follow-up.

### Indication for surgical referral

- Symptomatic defects or significant psychological distress or body image problems
- Failed prior repair

### Repair

**Timing:** Dependent on the degree of symptoms and anatomy. Bracing options are ideally started in early adolescence or pre-teens, but may still have some degree of success in older children. Surgical options are generally deferred until mid-to-late adolescence, if symptoms allow, to prevent problems with chest wall compliance, which may occur if done in younger patients.

### Treatment options

- **Ravitch repair\*:** [Refer to earlier mention]  
Some patients may be candidates for more limited resections
- **Pectus compression brace:** A custom brace made by Cook Children's Orthotics and Prosthetics.
  - Worn 16-23 hours a day for the first year and 12-16 hours the second year
  - Many patients are candidates for this non-operative treatment before considering surgical repair
  - Compliance is important for optimal results
  - Faster, more complete correction in younger patients

## Cook Children's Pediatric Surgery team

- José L. Iglesias, M.D., FACS, FAAP
- Kanika Bowen-Jallow, M.D., MMS, FACS, FAAP
- Chad E. Hamner, M.D., FACS
- Rodrigo Interiano, M.D., FACS
- Marty Knott, D.O., Ph.D.
- Daniel Lodwick, M.D., MS, MMS
- Thomas Rothenbach, M.D., FACS
- John Uffman, M.D., MPH, FACS



1500 Cooper St.  
Fort Worth, TX 76104  
682-885-7080 phone

4200 W. University Drive  
Prosper, TX 75078  
682-303-0719 phone



[cookchildrens.org/pediatric-surgery](https://cookchildrens.org/pediatric-surgery)

For referral forms and insurance information, visit [cookchildrens.org/professionals](https://cookchildrens.org/professionals)

Visit our paperless portal to access the referral platform and view mutual patients at [epiccarelink.cookchildrens.org](https://epiccarelink.cookchildrens.org)